Chronic Hypersensitivity Pneumonitis

Andrew Churg, MD, Nestor L. Muller, MD, PhD,† Julia Flint, MD,* and Joanne L. Wright, MD**

Abstract: Hypersensitivity pneumonitis (HP) is traditionally divided on clinical grounds into acute, subacute, and chronic stages. Most biopsy specimens come from patients in the subacute stage, in which there is a relatively mild, usually peribronchiolar, chronic interstitial inflammatory infiltrate, accompanied in most cases by poorly formed interstitial granulomas or isolated giant cells. However, the pathologic features in the chronic, ie, fibrotic stage, are poorly defined in the literature. These features are important to recognize because the chronic stage of HP is often associated with a poor prognosis. We reviewed 13 cases of chronic HP. Where information was available, exposures to the sensitizing agent had generally occurred over a long period of time. Three patterns of fibrosis were seen: 1) predominantly peripheral fibrosis in a patchy pattern with architectural distortion and fibroblast foci resembling, microscopically, usual interstitial pneumonia (UIP); 2) relatively homogeneous linear fibrosis resembling fibrotic nonspecific interstitial pneumonia (NSIP); and 3) irregular predominantly peribronchiolar fibrosis. In some instances, mixtures of the UIP-like and peribronchiolar patterns were found. In all cases, the presence of scattered poorly formed granulomas, or isolated interstitial giant cells, or sometimes only Schaumann bodies indicated the correct diagnosis. In 7 cases, areas of typical subacute HP were present as well. High-resolution CT scans showed variable patterns ranging from severe fibrosis, in some instances with an upper zone predominance, to predominantly ground glass opacities with peripheral reticulation. We conclude that, at the level of morphology, chronic HP may closely mimic UIP or fibrotic NSIP. If no areas of subacute HP are evident, the presence of isolated giant cells, poorly formed granulomas, or Schaumann bodies is crucial to arriving at the correct diagnosis, and the finding of peribronchiolar fibrosis may be helpful. Despite the presence of extensive fibrosis, some patients responded to removal from exposure and steroid therapy.

Key Words: hypersensitivity pneumonitis, pulmonary fibrosis, usual interstitial pneumonia, nonspecific interstitial pneumonia

(*Am J Surg Pathol* 2006;30:201–208)

Hypersensitivity pneumonitis (HP), also known as extrinsic allergic alveolitis, is a fairly common form of interstitial lung disease caused by inhalation of organic antigens and low molecular weight inorganic molecules. HP is usually divided clinically into three forms.[4,28,29] Acute HP is seen with exposure to high doses of sensitizing agent and is characterized by fever, chills, and cough developing 4 to 8 hours after exposure, with resolution usually complete by 24 to 48 hours.[4,28] Subacute HP is caused by intermittent or continuous exposure to lower doses of antigen and is characterized by the insidious onset of shortness of breath and clinical features of an interstitial lung disease without any obvious relation to an episode of exposure. Patients with subacute HP typically have bilateral ground glass poorly defined centrilobular nodules or diffuse ground glass opacities on high resolution CT scan.[10,21] Most cases of subacute HP appear to respond well to removal from antigen exposure and treatment with steroids.

Chronic HP is thought to develop from very low level persistent or recurrent exposure to an antigen and is separated from subacute HP by the presence of fibrosis on radiographic examination. Such patients also start with slowly progressive shortness of breath but frequently develop severe irreversible physiologic impairment. Several reports[19,27] have shown that HP patients with fibrosis on biopsy have a significantly worse prognosis than those without.

These observations emphasize the importance of accurate pathologic diagnosis of the type of HP present on biopsy. Most cases that come to biopsy are in the subacute stage, and the pathologic features are well defined. The classic case of subacute HP shows a fairly mild chronic interstitial inflammatory infiltrate with accentuation around the bronchioles, accompanied by isolated interstitial giant cells or poorly formed granulomas in about 70% of specimens.[22] However, very little is known about the pathologic features of chronic HP; the few available descriptions date from the 1960s[25] and are difficult to incorporate into the current classifications of interstitial lung disease. In this study, we have reviewed a series of cases of chronic HP to attempt to define the pathologic features and suggest methods for differentiating chronic HP from other fibrotic forms of interstitial pneumonia.

MATERIALS AND METHODS

Cases were retrieved from the consultation files of the authors. To qualify for inclusion, patients needed, clinically, to have an interstitial lung disease compatible with HP, and on biopsy needed to show a combination of diffuse interstitial fibrosis plus isolated interstitial giant cells or poorly formed granulomas, or Schaumann bodies. Only cases in which an attempt had been made to find an antigen were included. Information on chest radiographs or high-resolution CT scans were available for many cases, and when possible, actual films were reviewed.

After initial review of the slides, the fibrotic patterns were broken down into three categories: 1) resembling usual

From the Departments of *Pathology and †Radiology, University of British Columbia, Vancouver, British Columbia, Canada.
Reprints: Andrew Churg, MD, Department of Pathology, University of British Columbia, 2211 Wesbrook Mall, Vancouver, BC, Canada V6T 2B5 (e-mail: achurg@interchange.ubc.ca).
Copyright © 2006 by Lippincott Williams & Wilkins

Copyright © Lippincott Williams & Wilkins. Unauthorized reproduction of this article is prohibited.

interstitial pneumonia (UIP-like), 2) resembling nonspecific interstitial pneumonia (NSIP-like), and 3) peribronchiolar. These patterns are described in Results. In addition, note was made of the presence or absence of areas of ordinary, nonfibrotic, subacute HP as defined in the Introduction.

RESULTS

Table 1 summarizes the demographic, exposure/symptoms, and radiographic data. There were 6 males and 7 females, with an average age of 54 years (range, 13–74 years). Information on definite or possible sensitizing agents was available for 10 patients. Five had a history of exposure to birds (patient 6 bred parakeets) and in 4 of them exposure was known to have occurred for a considerable period, the longest being 12 years. Two patients were exposed to household mold, apparently from water damage, for periods of 4 and 8 years, and mold exposure was thought by the clinicians taking care of these patients to be the cause of their disease. One had been employed at a farm intermittently for periods up to 1 month over many years; he was known to have shoveled mushroom compost. One patient worked in a factory making plastics, but no specific information about the materials he worked with was available. Patient no. 7 had been exposed to wood dust and construction materials for many years, but his symptoms were present for less than 1 year. In the remaining patients, no obvious sensitizing agent could be found.

A variety of radiographic appearances were observed, all suggesting the presence of underlying fibrosis. Chest radiographs and CT scans demonstrated a reticular pattern, which ranged from mild to severe, and coarse interstitial markings, which varied from predominantly lower zone to predominantly upper zone (Table 1). On high-resolution CT, some cases showed a patchy or random distribution of reticulation, whereas others showed predominantly peripheral reticulation with honeycombing in a pattern resembling UIP. Four of the 8 patients who had a high-resolution CT had extensive bilateral ground glass opacities away from areas of reticulation. In a broad sense, the severity of the fibrotic changes on CT correlated with the severity of the fibrotic changes on biopsy, but considerable fibrosis was present in some cases despite minimal evidence of fibrosis on CT scan. Specific examples are illustrated with the histologic findings.

Histologically, three fundamental patterns of fibrosis were observed (Table 2). In 9 cases, there was a subpleural, patchy, pattern of generally paucicellular fibrosis with obliteration of the underlying lung structure and architectural distortion very much resembling that seen in usual interstitial pneumonia (Figs. 1, 2). The severity of the subpleural lesions varied considerably, although microscopic honeycombing was absent in most cases. Fibroblast foci associated with the peripheral fibrosis were present in all cases showing this pattern (Fig. 1). All cases with this pattern of fibrosis demonstrated isolated giant cells and/or granulomas (Figs. 1, 2) and 1 case also had Schaumann bodies. Giant cells and granulomas were found in both fibrotic and nonfibrotic areas.

Six cases showed only a UIP-like pattern of fibrosis, whereas in 3 cases UIP-like areas were mixed with

TABLE 1. Clinical and Radiographic Features

Case No.	Age (yr)/Sex	Duration of Exposure (yr)	Sensitizing Agent	Radiologic Findings	Therapy/Outcome
1	59/F	8	Mold	Upper zone fibrosis + centrilobular opacities + ground glass opacities (CT)	Steroids, improved (6 months)
2	61/F	10	Bird	Ground glass opacities + reticulation (CT)	Steroids, removal of bird, improved (8 months)
3	61/M	5	Bird	Upper zone reticular pattern (CT)	Steroids, no improvement (slow deterioration over 5 years)
4	68/F	4	Mold	Upper zone reticular pattern (CT)	NA
5	13/M	12	Bird (pigeon)	Coarse reticular pattern sparing bases (chest x-ray)	Steroids, improved, 1 year
6	65/F	10	Bird (breeder)	NA	NA
7	62/M	<1 (duration of symptoms) but many years of work in construction	?Wood dust or construction materials	Ground glass opacities + reticulation (CT)	Steroids, improved, 5 months
8	55/M	NA	Bird	NA	NA
9	25/M	Intermittent exposure over many years	Mushroom compost on farm	Centrilobular nodules + peripheral reticulation (CT)	NA
10	55/F	NA	Unknown	Lower zone reticular patterns (chest x-ray)	NA
11	47/F	9 months (duration of symptoms)	Unknown	Honeycombing, traction bronchiectasis, mosaic attenuation (CT), lower zone predominance	Steroids, improved, 3 months
12	60/M	NA	Plastics factory	NA	NA
13	74/F	NA	Unknown	Peripheral reticulation + septal lines + ground glass opacities (CT)	Steroids and cyclophosphamide, died 9 months after biopsy

NA, not applicable.

© 2006 Lippincott Williams & Wilkins

Copyright © Lippincott Williams & Wilkins. Unauthorized reproduction of this article is prohibited.

TABLE 2. Pathologic Features

Case No.	UIP-Like Areas	Fibroblast Foci	NSIP-Like Areas	Peribronchiolar Fibrosis	Subacute HP Areas	Giant Cell/Granulomas	Schaumann Bodies
1	Yes	Yes	No	No	Yes	Both	No
2	Yes	Yes	No	No	Yes	Giant cells	No
3	Yes	Yes	No	No	Yes	Giant cells	No
4	No	Yes	Yes	No	No	Both	No
5	No	No	Yes	No	No	Giant cells	Yes
6	Yes	Yes	No	Yes	No	Both	Yes
7	Yes	Yes	No	No	Yes	Both	No
8	Yes	Yes	No	No	Yes	Giant cells	No
9	No	No	Yes	No	Yes	Granulomas	No
10	Yes	Yes	No	No	Yes	Granulomas	No
11	No	No	Yes	No	No	Giant cells	No
12	Yes	Yes	No	Yes	No	Both	No
13	Yes	Yes	No	Yes	No	Giant cells	No

peribronchiolar fibrosis. Six cases with UIP-like areas also had focal areas of typical subacute HP (Fig. 1). UIP-like areas were seen in cases with bird and mold exposure and in the 1 patient in whom there was exposure to wood dust and construction materials.

The second pattern was a homogeneous linear fibrosis that more or less followed the original underlying architecture (Fig. 3) and very much resembled fibrotic NSIP. NSIP-like areas were found in 4 cases, none of which had UIP-like foci. Only 1 case with an NSIP-like pattern of fibrosis also had areas of subacute HP and 1 had fibroblast foci. The NSIP-like pattern was seen in patients with bird exposure, mold exposure, and mushroom compost exposure.

The third pattern consisted of irregular fibrosis in a partially peribronchiolar distribution (Figs. 4, 5). This pattern was seen in 3 patients; however, in all instances, UIP-like fibrosis was also present in a subpleural location, and sometimes there was continuous, albeit irregular, fibrosis between the peribronchiolar and subpleural regions (Figs. 4, 5). This pattern was found in a patient with bird exposure, the man who worked in a plastics factory, and in 1 patient with unknown exposure. None of these patients had areas of subacute HP.

Information on treatment and at least short-term outcome was available for 7 individuals (Table 1). All were treated with steroids and, where the antigen was known, removal from exposure. Five patients had radiographic or functional improvement with steroid therapy, including 2 patients with bird exposure, 1 with mold exposure, 1 with wood dust/construction materials exposure, and 1 patient without a known exposure. One patient with bird exposure had slow deterioration, and 1 patient with unknown exposure progressed rapidly after diagnosis and died of disease despite the addition of Cytoxan therapy. Of the patients who improved, 3 had a UIP-like picture on biopsy and 2 an NSIP-like picture; the two patients whose condition did not improve had a UIP-like picture.

DISCUSSION

The presence of fibrosis on lung biopsy in cases of HP appears to be an important prognostic factor. Perez-Padilla et al[19] studied 78 patients with HP. The overall 5-year survival was 71%. When they separated the biopsies by extent of histologic fibrosis, those with greater than 50% fibrosis (not further defined) had a 4-year survival of 37%, whereas those with less than 50% had a 4-year survival of 75%. Similarly, Vourlekis et al[27] examined 72 patients with HP and labeled cases as "fibrotic" if there was increased interstitial collagen in more than 5% of the total lung parenchyma or if honeycombing was present. Patients with fibrosis had a significantly greater restrictive impairment than those without. The median survival of patients with fibrosis was 7.1 years, whereas for those without fibrosis it was greater than 20 years.

Although the studies just cited emphasize the importance of fibrosis as a predictor of survival, they do not provide any information about the morphologic patterns of fibrosis that were present. This is an important question because, as is clear from the data in Results, chronic HP may produce fibrotic reactions that mimic other types of interstitial lung disease. The literature in general on this question is sparse. Seal et al[25] produced one of the earliest and most detailed reports, but unfortunately both their descriptions and illustrations are difficult to interpret in light of our current understanding of patterns of interstitial fibrosis. They do illustrate gross specimens with upper zone honeycombing and describe both "linear" (possibly equivalent to NSIP-like) and peribronchiolar fibrosis. Vourlekis et al[26] reported 6 patients with clinically documented HP and a histologic picture of NSIP on biopsy; 3 of these showed a mixture of interstitial inflammation and fibrosis and 1 showed a fibrotic pattern with honeycombing. Similarly, in the original description of NSIP by Katzenstein and Fiorelli,[15] 2 of their cases with mixed interstitial inflammation and fibrosis had loosely formed granulomas. Several of their patients had possible sensitizing exposures, and the authors speculated that some cases of NSIP might represent HP.

In assembling this series, we included only cases in which there was a pattern of interstitial fibrosis mixed, in all instances, with the more characteristic interstitial giant cells and poorly formed granulomas of typical HP. As well, 7 of our 13 cases had focal areas of very typical cellular nonfibrotic

Copyright © Lippincott Williams & Wilkins. Unauthorized reproduction of this article is prohibited.

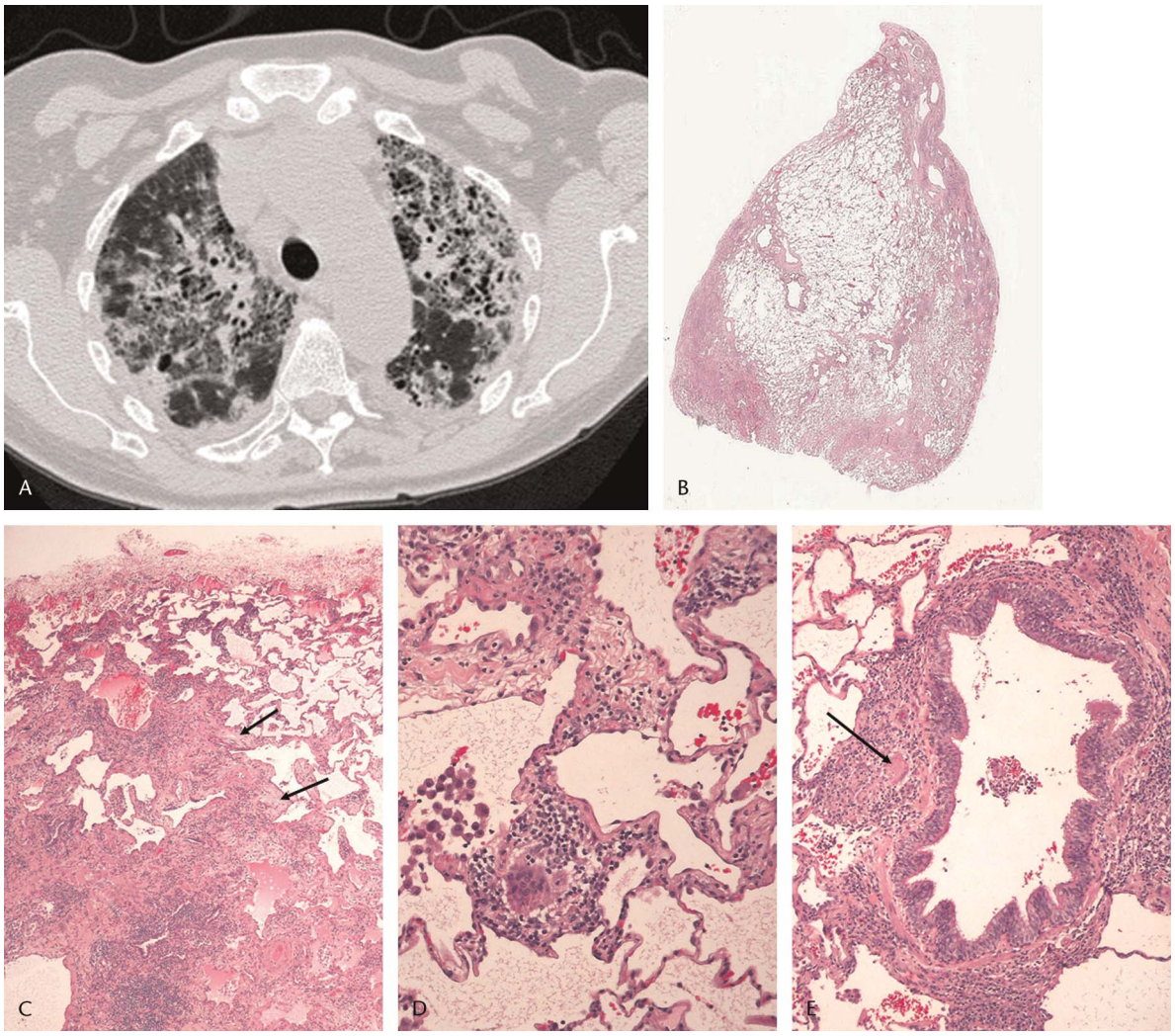

FIGURE 1. Chronic HP caused by mold exposure (case no. 1). A, High-resolution CT at the level of the aortic arch shows extensive bilateral upper lobe reticulation and honeycombing. Also present are a few poorly defined nodular opacities. The fibrosis in this case was predominantly upper zonal. B, Low power view of biopsy showing peripheral fibrosis with architectural distortion in a pattern resembling UIP. C, Higher power view of fibrotic area showing dense irregular fibrosis and fibroblast foci (arrows), mimicking UIP. D, Subacute HP-like area with an isolated interstitial giant cell and surrounding chronic inflammation. E, Membranous bronchiole with surrounding chronic inflammation and a giant cell (arrow). This image also show a pattern typical of subacute HP. *a+*

subacute HP, a finding that certainly supports the diagnosis of chronic HP. In addition, we only selected cases for which there was a definite history of antigen exposure or in which a thorough search had been made by the clinicians involved for an antigen. Nine subjects had exposures known to be associated with HP. HP in individuals who have pet birds or breed pigeons is well described. Exposure to mushrooms and mushroom compost is also an accepted cause of HP.[20,28] Although we have no details about the work performed by the subject employed in the plastics factory, plastics production may involve exposure to isocyanates, methacrylates, trimellitic anhydride, and epoxy resins, particularly phthalic anhydrides, all agents that have been associated with HP.[8,20,24,28] Exposure to household molds is another well-established cause of HP,[9,14] and in some locations, such as Japan, is associated with relatively large numbers of cases.[2]

In the remaining cases, there was no documented sensitizing exposure, and these cases should be regarded as more speculative diagnoses (although 1 of these cases, case no. 10, did have areas of subacute HP and 2 cases had peribronchiolar fibrosis). However, the lack of a good exposure history is a common finding in large series of HP patients and appears to be a particular problem with chronic HP cases,[3,23] possibly because the exposures are often low and persistent and may not be obvious to the patient. Thus, in the 72 carefully worked up patients with subacute or chronic HP described by Vourlekis et al,[27] and all diagnosed on biopsy, no sensitizing agent could be found in 38%. Similarly, in 27 cases of subacute HP reported by Coleman and Colby,[6] no specific exposure could be found in 17 (63%).

Our findings suggest that chronic HP biopsies may show three different patterns of fibrosis: a UIP-like pattern, an

© 2006 Lippincott Williams & Wilkins

Copyright © Lippincott Williams & Wilkins. Unauthorized reproduction of this article is prohibited.

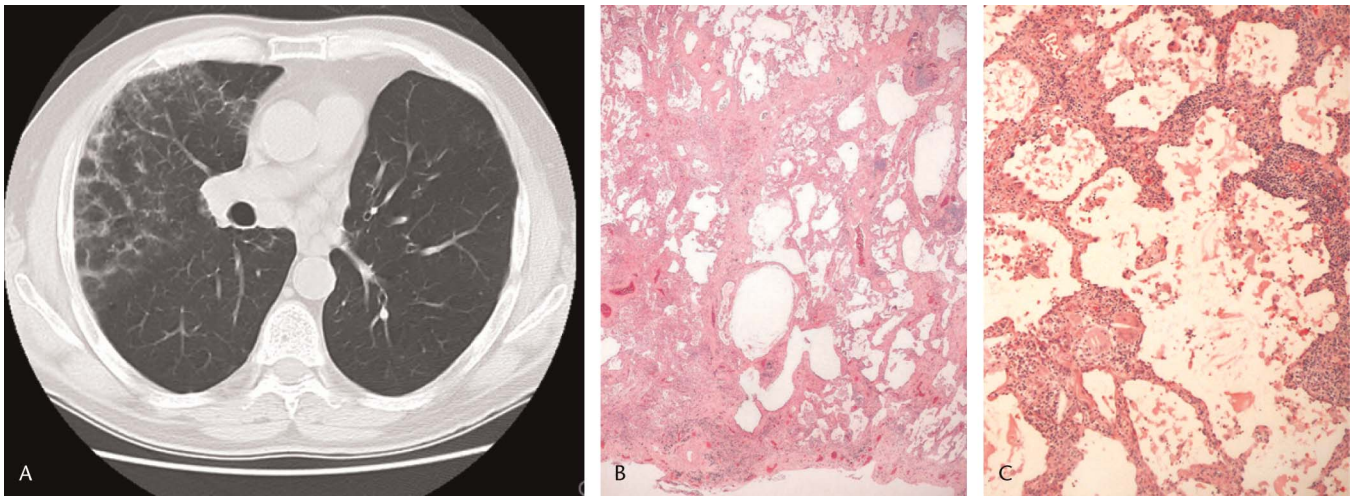

FIGURE 2. Chronic HP in a man exposed to wood dust and construction materials (case no. 7). A, CT scan image shows ground glass opacities, a few centrilobular nodular opacities, and mild peripheral reticulation in the right lung. Minimal abnormalities are evident in the left lung. The presence of reticulation suggests underlying fibrosis. B, Low power view showing marked but patchy fibrosis resembling idiopathic UIP. C, Area of subacute HP with a chronic interstitial inflammatory infiltrate and a poorly formed granuloma. *a+*

NSIP-like pattern, and an irregular peribronchiolar pattern. These patterns did not all occur in the same biopsy: in particular, the UIP-like pattern was seen either by itself or in association with peribronchiolar fibrosis, whereas the NSIP-like pattern was never associated with a UIP-type picture. Whereas the NSIP-like pattern was, for all practical purposes, morphologically indistinguishable from idiopathic NSIP, the UIP-like pattern was often not a perfect match to idiopathic UIP. These cases did not show the perilobular distribution of fibrosis that is found in many cases of idiopathic UIP, and honeycombing was minimal or absent, whereas microscopic honeycombing is common in UIP biopsies. However, the lack of microscopic honeycombing might represent simply a sampling phenomenon. As well, in some cases, there was fairly minimal architectural distortion, but it was always peripheral and was associated with fibroblast foci, typical findings in UIP. The finding of peribronchiolar fibrosis was particularly helpful in the few cases in which it occurred because this is not a feature of UIP; this feature was particularly well seen at low power, where the distinctive combination of peribronchiolar fibrosis and subpleural UIP-like fibrosis was apparent.

Our findings also raise the question of how many cases with these fibrotic patterns but lacking giant cells, granulomas, Schaumann bodies, or subacute HP might actually represent chronic HP. Giant cells and granulomas are known to disappear over time in HP cases, particularly if exposure to the

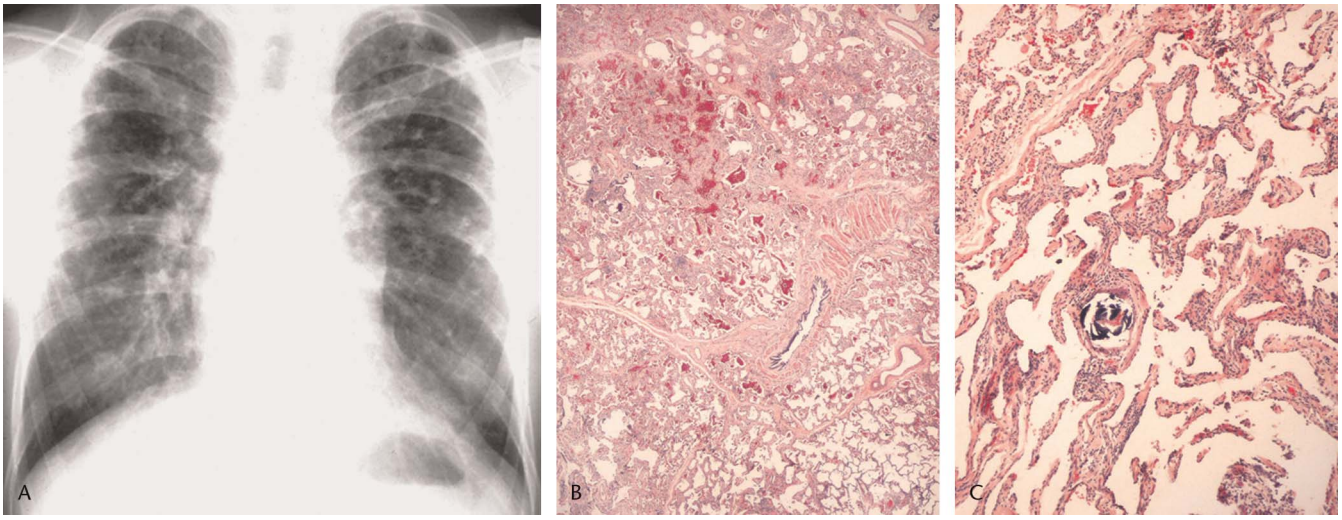

FIGURE 3. Chronic HP in a child with long term pigeon exposure (case no. 5). A, Chest radiograph shows reticular pattern in the middle and upper lung zones. B, Low power view shows homogeneous linear fibrosis in an NSIP-like pattern. C, Another area demonstrating both linear fibrosis and a Schaumann body with surrounding giant cells. *a+*

© 2006 Lippincott Williams & Wilkins

Copyright © Lippincott Williams & Wilkins. Unauthorized reproduction of this article is prohibited.

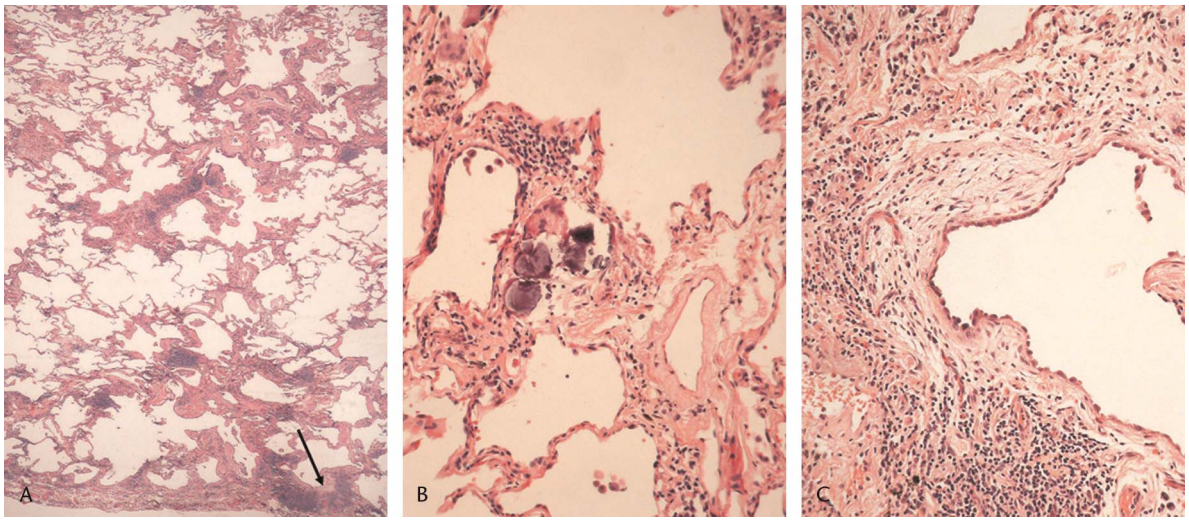

FIGURE 4. Chronic HP in a woman with long term bird exposure (case no. 6). A, Low power view showing a combination of irregular peribronchiolar fibrosis and peripheral fibrosis with some early architectural distortion. A fibroblast focus is present at the arrow. B, Another field showing Schaumann bodies. C, Another area showing a fibroblast focus near the pleura. *a+*

antigen has ceased.[7,11,25] Schaumann bodies are the hallmarks of old granulomas, and these may serve as a useful guide to the correct diagnosis if giant cells and granulomas cannot be found, but it is unclear how often they occur; in the present series, Schaumann bodies were seen in only 2 cases. As well, giant cells and granulomas are thought to occur in only about 70% of ordinary subacute HP[22]; presumably, cases lacking giant cells and granulomas in the subacute stage would simply appear as various forms of fibrotic interstitial lung disease if they reached the chronic stage, and there is evidence that this situation exists in some patients whose biopsies show a pattern of NSIP. In the 6 well-documented cases of HP with a biopsy picture of NSIP described by Vourlekis et al,[26] none showed giant cells, granulomas, or Schaumann bodies. Along this line, Jacobs et al[14] have recently suggested that chronic HP is frequently underdiagnosed, and that workup for sensitization (for example, by finding specific precipitating antibodies or by challenge testing) indicates that some cases that appear morphologically to be other forms of interstitial pneumonias, are actually chronic HP; the same conclusion has been reached by Ando et al.[3] These observations suggest that, if there is a known history of exposure to a possible sensitizing agent but the biopsy shows only NSIP-like or UIP-like fibrosis, the possibility of chronic HP should be raised, so that the patient can be removed from exposure and treated.

Radiographic findings are often useful in suggesting the diagnosis of chronic HP, particularly when the differential diagnosis is UIP or NSIP. The typical radiographic manifestations of chronic HP consist of a medium to coarse reticular pattern and loss of lung volume. CT findings helpful in distinguishing chronic HP from UIP include relative sparing of the lung bases, greater extent of ground glass opacities, the presence of lobular areas of mosaic attenuation or air trapping, and centrilobular nodular opacities in HP. However, it is well accepted that there is considerable overlap between the high-resolution CT findings of HP and those of UIP and NSIP.[13,17] Although the fibrosis of chronic HP was traditionally thought to involve the upper zones of the lung,[12] more recent studies have shown that indeed it more commonly involves mainly the middle third or the lower lung zones.[1,17] In a study that included 36 patients with UIP (n = 33) or desquamative interstitial pneumonia (DIP) (n = 3) and 27 patients with HP, two independent radiologists were able to make a confident separation based on the high-resolution CT findings in only 62% of cases.[17] Furthermore, when they were confident in their diagnosis of UIP or HP, they were correct in only 90% of interpretations. Similarly, Hartman et al,[13] in a review of the high-resolution CT findings in 50 patients with NSIP, found that in 10 patients (20%) the findings mimicked those of HP. The difficulties in making this distinction can be can be seen in our case no. 13, which radiographically mimics UIP (Fig. 5a).

In addition to NSIP and UIP, the morphologic differential diagnosis of cases with these appearances, at least in theory, includes fibrotic forms of sarcoidosis. In general, this differential should not present a problem because granulomas are numerous in sarcoid, and scarring in sarcoid commonly forms fibrotic nodules with granulomas around the periphery. The granulomas in sarcoid are also much more sharply delineated than those in chronic HP, usually with a hyalinized rim of fibrous tissue around the perimeter. Finally, in our experience, fibrotic forms of sarcoid usually do not show either NSIP or UIP-like areas of fibrosis. So-called hot tub lung, a form of HP caused by sensitization to atypical mycobacteria that grow in hot tubs and saunas, is also in the morphologic differential diagnosis.[16] Hot tub lung typically has numerous large, sometimes necrotizing, granulomas that may be located in small airway lumens, and an associated interstitial inflammatory infiltrate, but not interstitial fibrosis. Organisms can be demonstrated by culture or special stain.

Fibrotic forms of collagen vascular disease may also produce problems in differential diagnosis because they can show an NSIP picture or a UIP picture and, particularly in

© 2006 Lippincott Williams & Wilkins

Copyright © Lippincott Williams & Wilkins. Unauthorized reproduction of this article is prohibited.

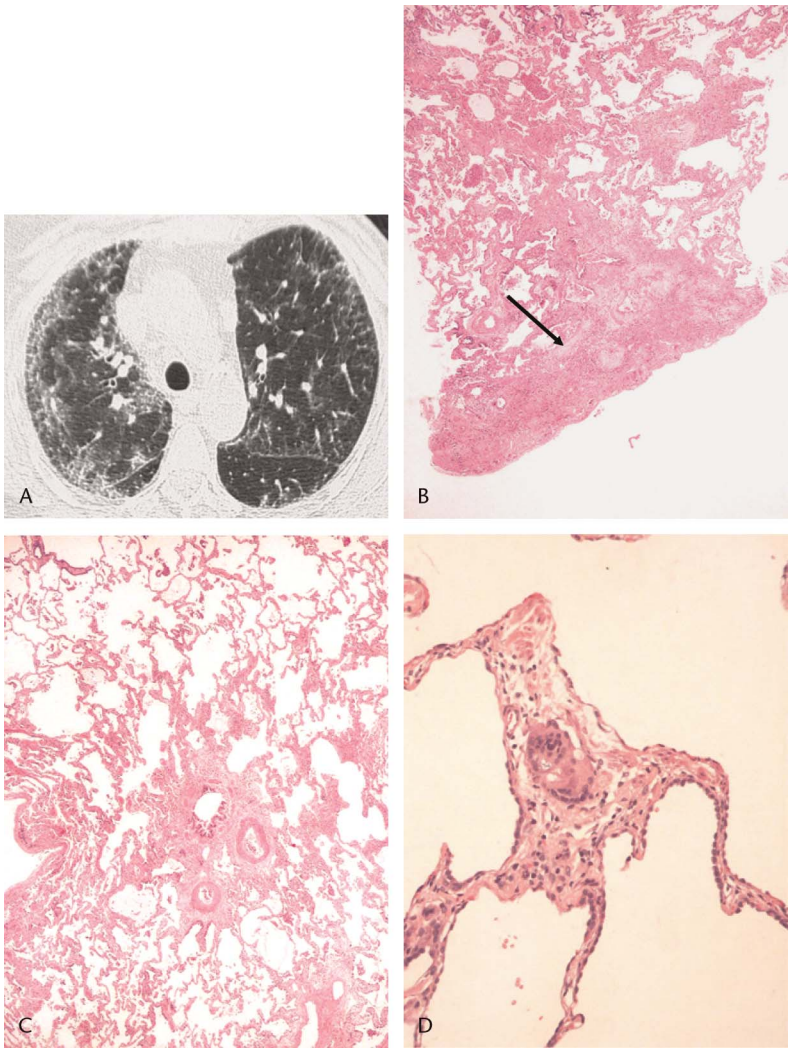

FIGURE 5. Chronic HP in a patient with unknown exposure (case no. 13). A, High-resolution CT scan images show bilateral reticular pattern and focal ground glass opacities. The appearance resembles that of UIP. B, Lower power view showing irregular peripheral fibrosis with architectural distortion and a fibroblast focus (arrow). C, Another area demonstrating peribronchiolar fibrosis extending into surrounding alveolar walls. The airway wall itself is fibrotic, suggesting an old inflammatory process. D, Higher power view of another field showing an interstitial giant cell. *a+*

patients with rheumatoid arthritis, peribronchiolar fibrosis caused by inflammatory disease in the small airways may be present as well.[18] However, in general, collagen vascular disease cases should not have isolated granulomas or giant cells. Drug reactions are potentially more of a problem because some drugs can produce poorly formed granulomas as well as interstitial inflammation and interstitial fibrosis. As a rule, drug reactions are exclusionary diagnoses, so that a history of drug administration and a proper temporal relation to drug administration are crucial to the diagnosis.

Also in the differential are several recently described forms of fibrotic interstitial pneumonias characterized by predominantly peri-airway fibrosis. They have been labeled "airway centered interstitial fibrosis,"[5] "idiopathic bronchiolocentric interstitial pneumonia,"[30] and "peribronchiolar metaplasia."[7] All are characterized by a fibrotic process that damages bronchioles and radiates through the interstitium away from the bronchioles, sometimes reaching the pleura, but without significant architectural distortion and without fibroblast foci or other evidence of recent activity. In all of these conditions, there is extensive bronchiolar metaplasia overlying the fibrotic alveolar walls. This type of bronchiolar metaplasia was not present in any of or cases, nor was the peribronchiolar fibrosis as regular in our cases of chronic HP as it was in these conditions. In the series of Churg et al[5] and Yousem and Dacic,[30] none of the cases had interstitial giant cells or granulomas, but a few small granulomas were seen in 3 of the 15 cases of Fukuoka et al.[7] In all 3 papers, the authors raised the question of whether these might be variants of chronic HP, and a few cases in each series had suggestive exposures. For example, in the report by Churg et al[5] on patients from Mexico City, 2 patients had pigeon exposure but did not have precipitating antibodies and were not considered to have HP. The relationship of these lesions to chronic HP remains unclear.

Isolated small granulomas or interstitial giant cells are occasionally seen in biopsies from patients with what are thought to be other (non-HP) forms of interstitial pneumonias. In most of our cases, the combination of morphologic findings (including subacute HP), radiographic findings, and exposure history established the diagnosis of chronic HP, but the possibility remains that some of our cases, particularly those without clear exposure histories, might represent other forms

Copyright © Lippincott Williams & Wilkins. Unauthorized reproduction of this article is prohibited.

of interstitial lung disease in which there happen to be incidental granulomas or isolated giant cells. It is very difficult to rule out this possibility, and the diagnosis in these cases, as noted above, is somewhat speculative; nonetheless, we suggest that, for reasons of treatment and prognosis, the possibility that such biopsies represent chronic HP should at least be raised.

Our primary aim in this paper was to describe pathologic patterns of chronic HP, and we were able to obtain only very limited, and often short-term, follow-up data. This limited information does not allow us to demonstrate any obvious relationships between pathologic pattern and outcome; however, the important point is that, despite the presence of considerable fibrosis, some patients improved, at least over the short term, with removal from exposure and steroid therapy, even in some cases with UIP-like areas on the biopsy. Short-term improvements may not be indicative of long-term outcome; nonetheless, the overall prognosis for chronic HP appears to be better than that of UIP,[19,27] so the distinction is valuable.

In summary, chronic HP often has a fibrotic component that can mimic the idiopathic interstitial pneumonias. The presence of giant cells, granulomas, Schaumann bodies, and areas of subacute HP, along with peribronchiolar fibrosis, when present, allow one to arrive at the correct diagnosis. Radiographic and exposure information is also very helpful. What fraction of chronic HP cases lack these diagnostic features and look pathologically, like UIP or fibrotic NSIP is not known. If there is a suggestive exposure history, the possibility of chronic HP probably should be raised in a case that pathologically looks like UIP or NSIP because removal from exposure and therapy may result in clinical improvement.

REFERENCES

1. Adler BD, Padley SP, Muller NL, et al. Chronic hypersensitivity pneumonitis: high-resolution CT and radiographic features in 16 patients. *Radiology.* 1992;185:91–95.
2. Ando M, Suga M, Nishiura Y, et al. Summer-type hypersensitivity pneumonitis. *Intern Med*. 1995;34:707–712.
3. Ando M, Suga M, Kohrogi H. A new look at hypersensitivity pneumonitis. *Curr Opin Pulm Med*. 1999;5:299–304.
4. Bourke SJ, Dalphin JC, Boyd G, et al. Hypersensitivity pneumonitis: current concepts. *Eur Respir J.* 2001;32(suppl):81–92.
5. Churg A, Myers J, Suarez T, et al. Airway centered interstitial fibrosis: a distinct form of aggressive diffuse lung disease. *Am J Surg Pathol.* 2004;28:62–68.
6. Coleman A, Colby TV. Histologic diagnosis of extrinsic allergic alveolitis. *Am J Surg Pathol*. 1988;12:514–518.
7. Fukuoka J, Franks TJ, Colby TV, et al. Peribronchiolar metaplasia: a common histologic lesion in diffuse lung disease and a rare cause of interstitial lung disease. Clinicopathologic features of 15 cases. *Am J Surg Pathol*. 2005;29:948–954.
8. Grammer LC, Shaughnessy MA, Lowenthal M, et al. Risk factors for immunologically mediated respiratory disease from hexahydrophthalic anhydride. *J Occup Med*. 1994;36:642–646.
9. Greenberger PA. Mold-induced hypersensitivity pneumonitis. *Allergy Asthma Proc*. 2004;25:219–223.
10. Hansell DM, Moskovic E. High-resolution computed tomography in extrinsic allergic alveolitis. *Clin Radiol*. 1991;43:8–12.
11. Hapke EJ, Seal RM, Thomas GO, et al. Farmer's lung: a clinical, radiographic, functional, and serological correlation of acute and chronic stages. *Thorax*. 1968;23:451–468.
12. Hargreave F, Hinson KF, Reid L, et al. The radiological appearances of allergic alveolitis due to bird sensitivity (bird fancier's lung). *Clin Radiol*. 1972;23:1–10.
13. Hartman TE, Swensen SJ, Hansell DM, et al. Nonspecific interstitial pneumonia: variable appearance at high-resolution chest CT. *Radiology.* 2000;217:701–705.
14. Jacobs RL, Andrews CP, Coalson J. Organic antigen-induced interstitial lung disease: diagnosis and management. *Ann Allergy Asthma Immunol*. 2002;88:30–41.
15. Katzenstein AL, Fiorelli RF. Nonspecific interstitial pneumonia/fibrosis: histologic features and clinical significance. *Am J Surg Pathol*. 1994;18: 136–147.
16. Khoor A, Leslie KO, Tazelaar HD, et al. Diffuse pulmonary disease caused by nontuberculous mycobacteria in immunocompetent people (hot tub lung). *Am J Clin Pathol*. 2001;115:755–762.
17. Lynch DA, Newell JD, Logan PM, et al. Can CT distinguish hypersensitivity pneumonitis from idiopathic pulmonary fibrosis? *AJR Am J Roentgenol*. 1995;165:807–811.
18. Myers JL. Idiopathic interstitial pneumonias. In: Churg AM, Myers JL, Tazelaar HD, et al, eds. *Thurlbeck's Pathology of the Lung*, 3rd ed. New York: Thieme, 2005:563–600.
19. Perez-Padilla R, Salas J, Chapela R, et al. Mortality in Mexican patients with chronic pigeon breeder's lung compared with those with usual interstitial pneumonia. *Am Rev Respir Dis*. 1993;148:49–53.
20. Pickering CAC, Newman Taylor AJ. Extrinsic allergic bronchioloalveolitis (hypersensitivity pneumonitis). In: WR Parkes, ed. *Occupational Lung Disorders*, 3rd ed. London: Butterworth Heinemann, 1994: 667–709.
21. Remy-Jardin M, Remy J, Wallaert B, et al. Subacute and chronic bird breeder hypersensitivity pneumonitis: sequential evaluation with CT and correlation with lung function tests and bronchoalveolar lavage. *Radiology.* 1993;189:111–118.
22. Reyes CN, Wenzel FJ, Lawton BR, et al. The pulmonary pathology of farmer's lung disease. *Chest*. 1982;81:142–146.
23. Reynolds HY. Hypersensitivity pneumonitis: correlation of cellular and immunologic changes with clinical phases of disease. *Lung*. 1988;166: 189–208.
24. Scherpereel A, Tillie-Leblond I, Pommier de Santi P, et al. Exposure to methyl methacrylate and hypersensitivity pneumonitis in dental technicians. *Allergy.* 2004;59:890–892.
25. Seal RM, Hapke EJ, Thomas GO, et al. The pathology of the acute and chronic stages of farmer's lung. *Thorax*. 1968;23:469–489.
26. Vourlekis JS, Schwarz MI, Cool CD, et al. Nonspecific interstitial pneumonitis as the sole histologic expression of hypersensitivity pneumonitis. *Am J Med*. 2002;112:490–493.
27. Vourlekis JS, Schwarz MI, Cherniack RM, et al. The effect of pulmonary fibrosis on survival in patients with hypersensitivity pneumonitis. *Am J Med*. 2004;116:662–668.
28. Wild LG, Lopez M. Hypersensitivity pneumonitis: a comprehensive review. *J Invest Allerg Clin Immunol*. 2001;11:3–15.
29. Yi ES. Hypersensitivity pneumonitis. *Crit Rev Clin Lab Sci*. 2002;39: 581–629.
30. Yousem SA, Dacic S. Idiopathic bronchiolocentric interstitial pneumonia. *Mod Pathol*. 2002;15:1148–1153.

© 2006 Lippincott Williams & Wilkins

Copyright © Lippincott Williams & Wilkins. Unauthorized reproduction of this article is prohibited.